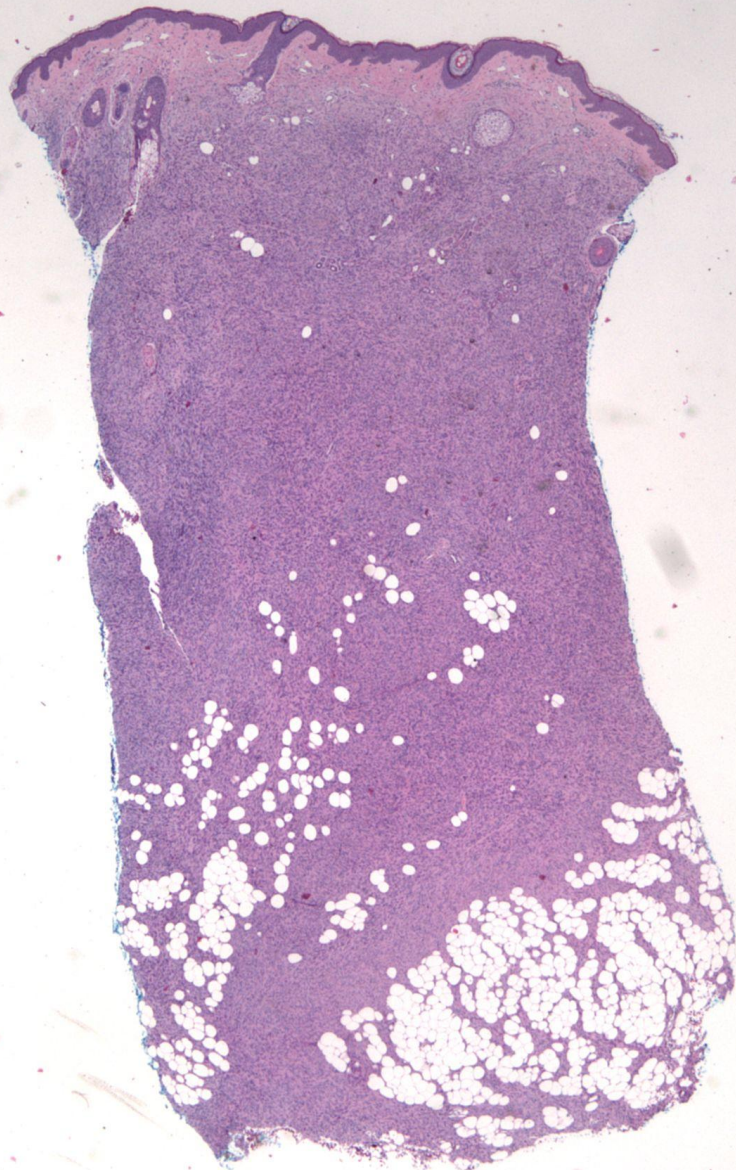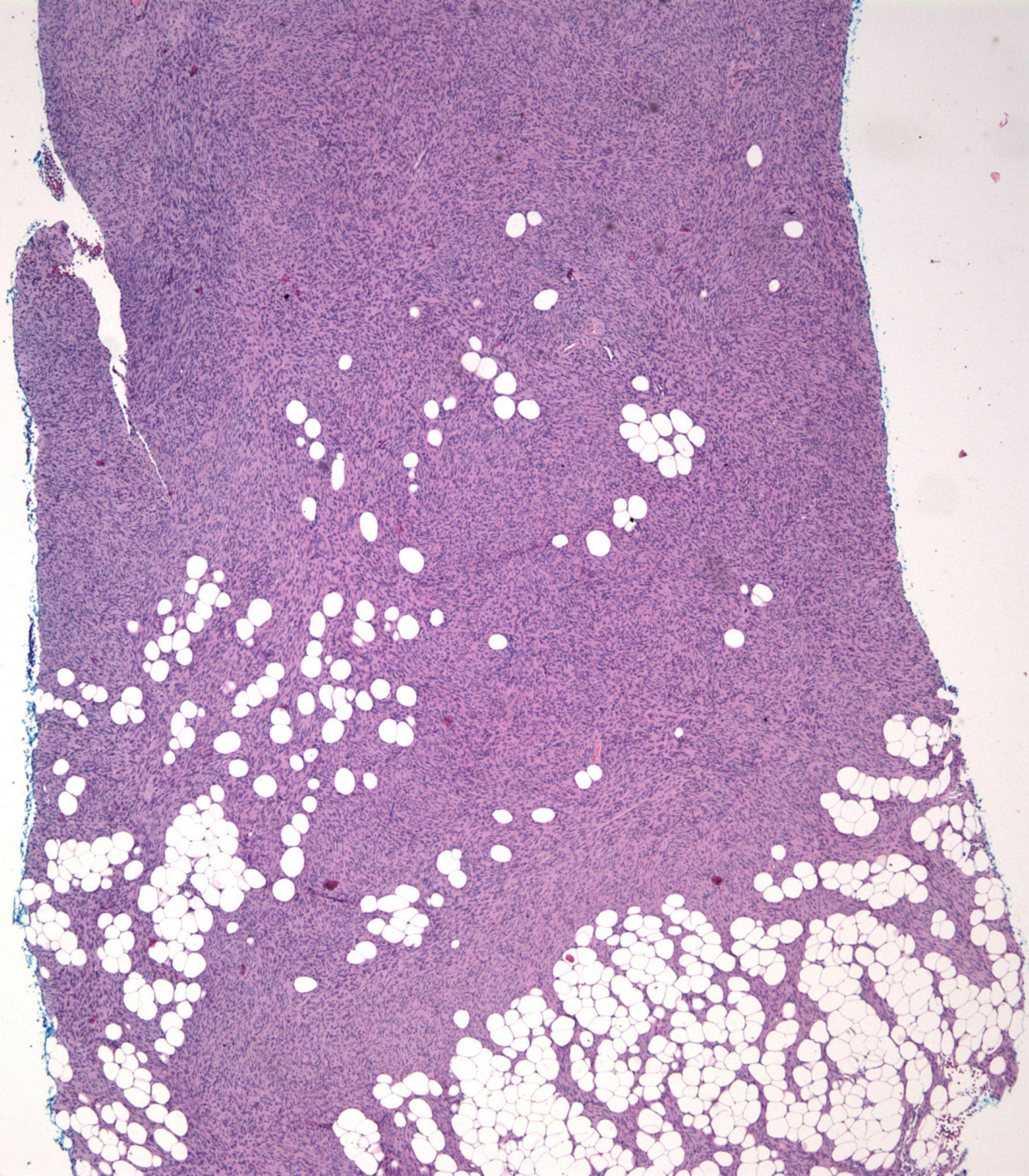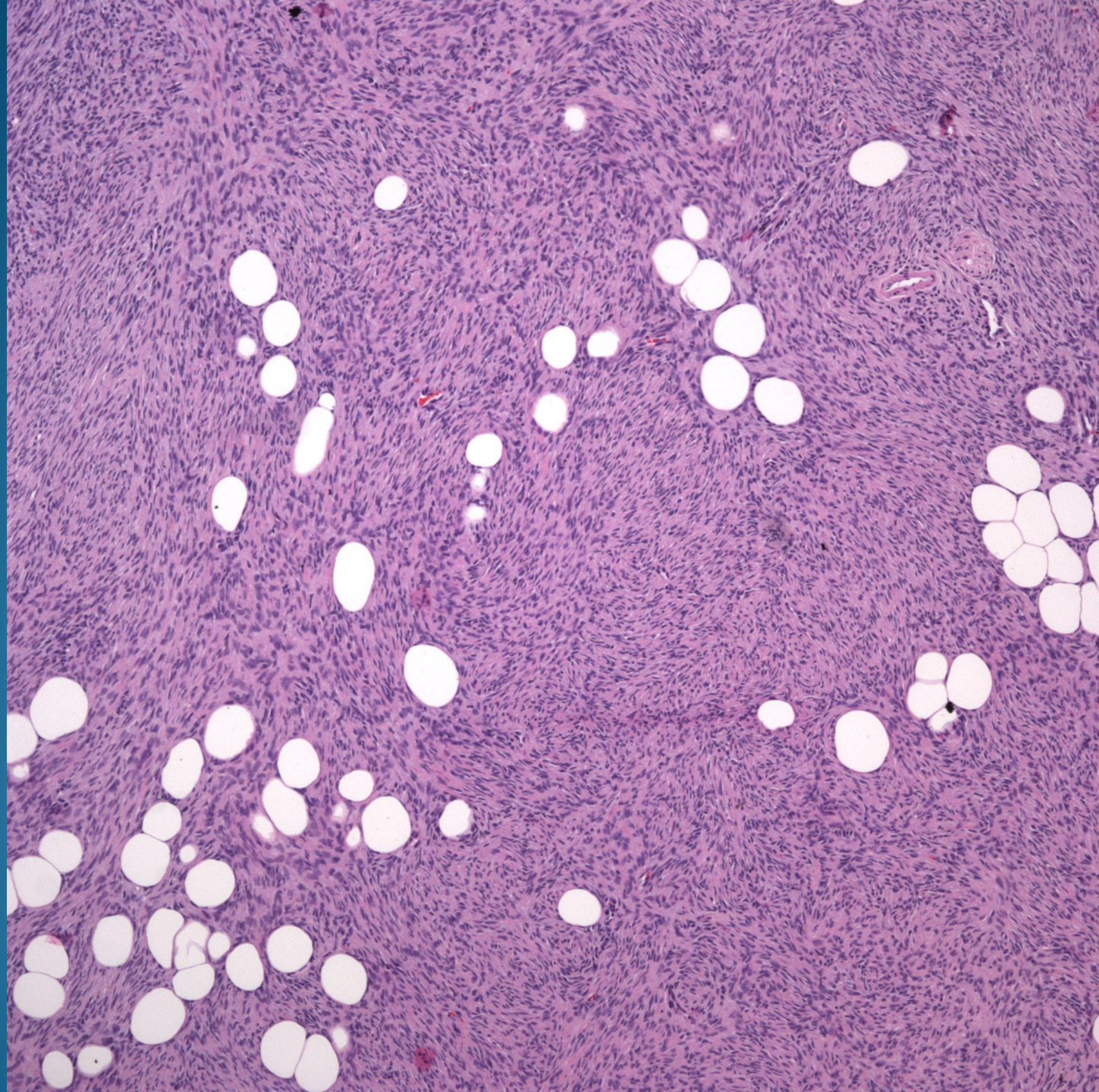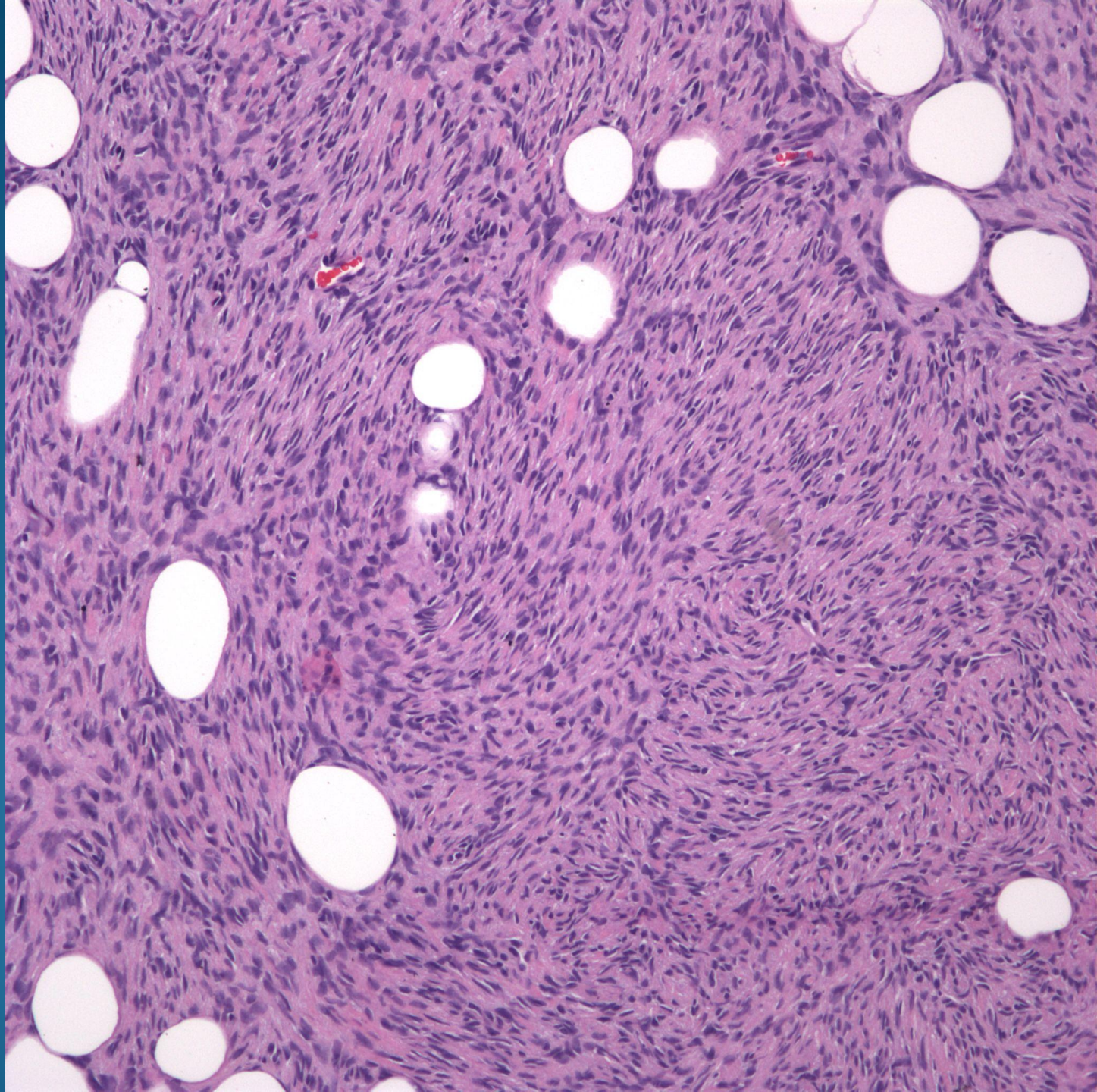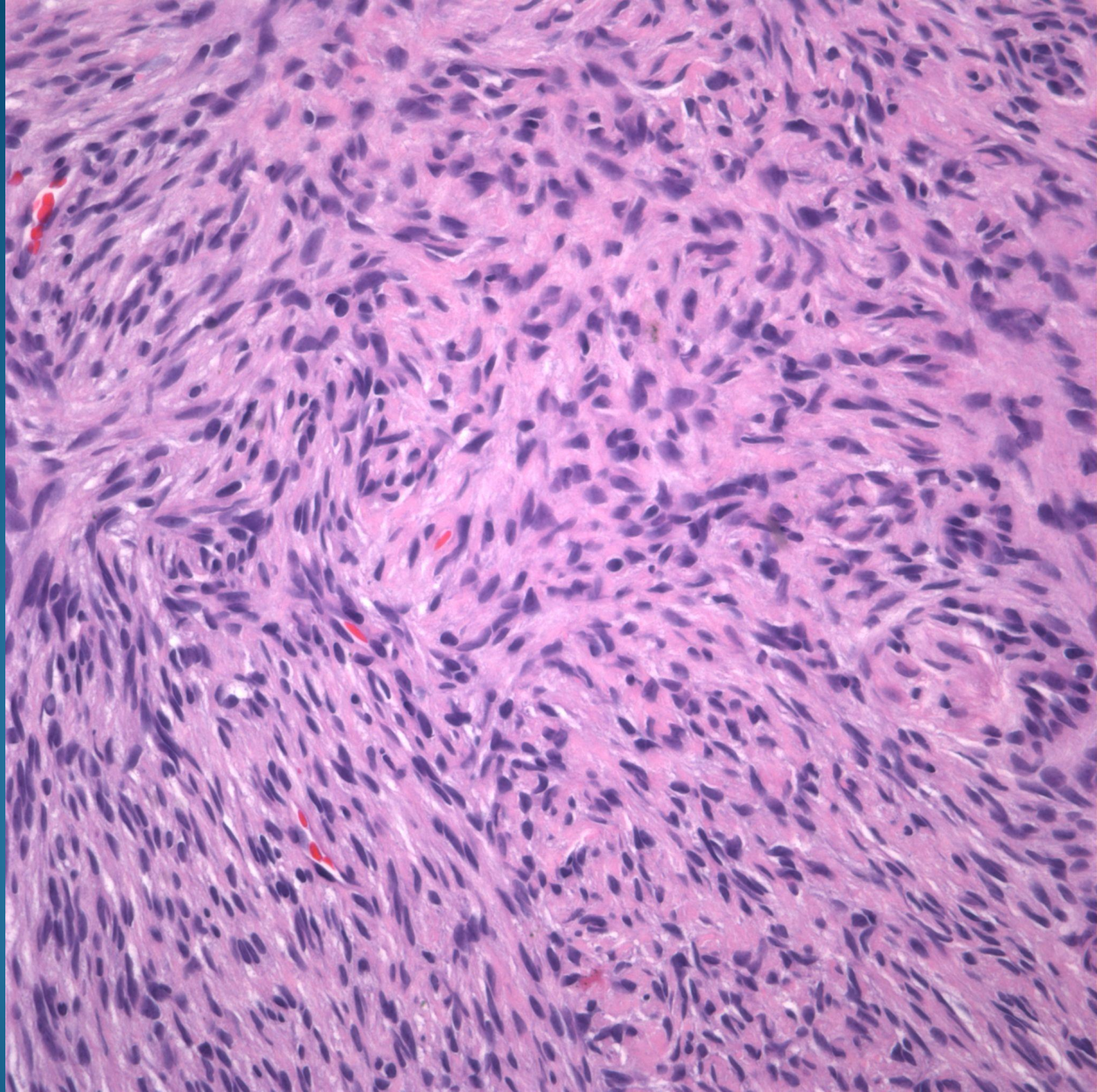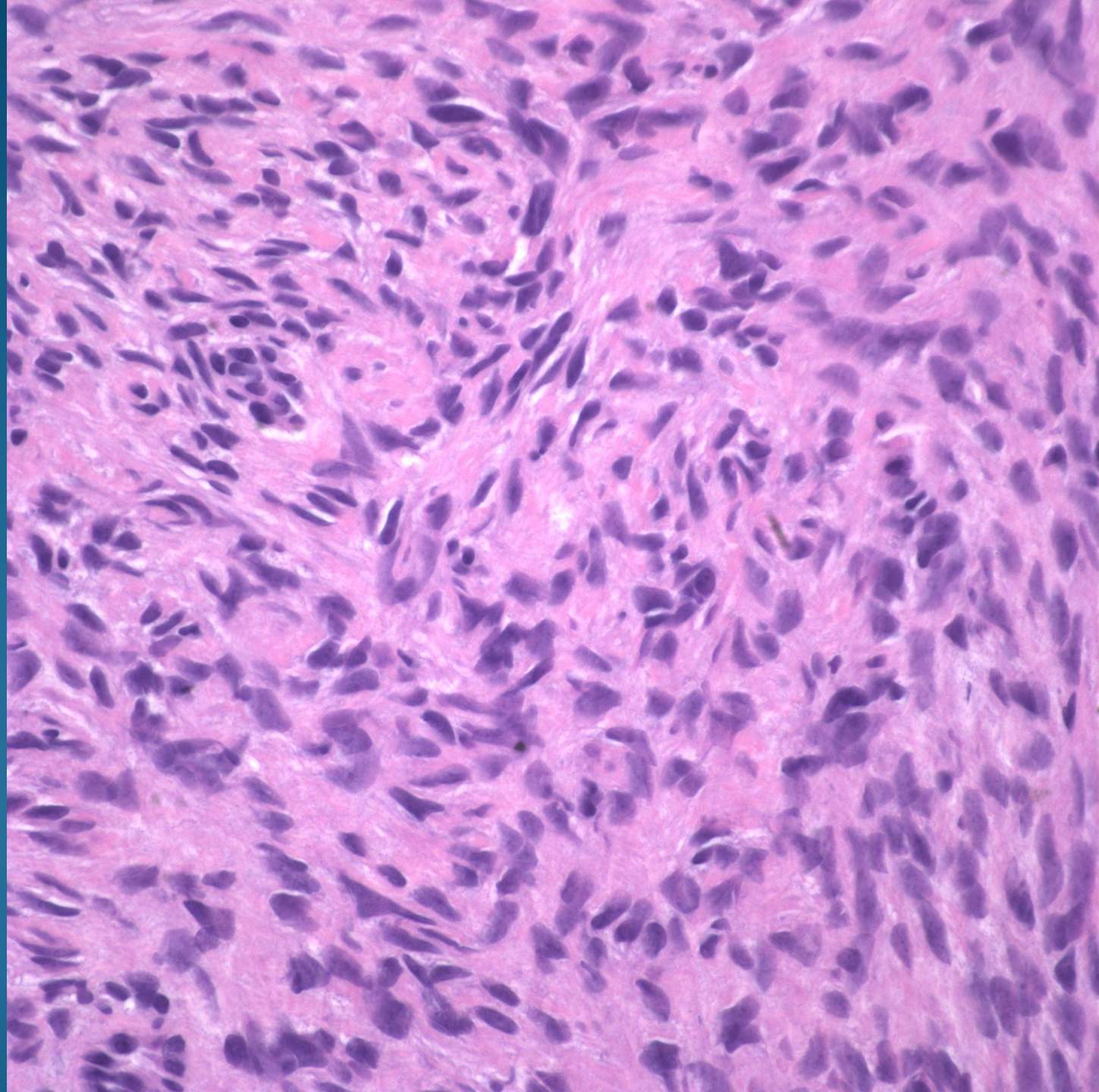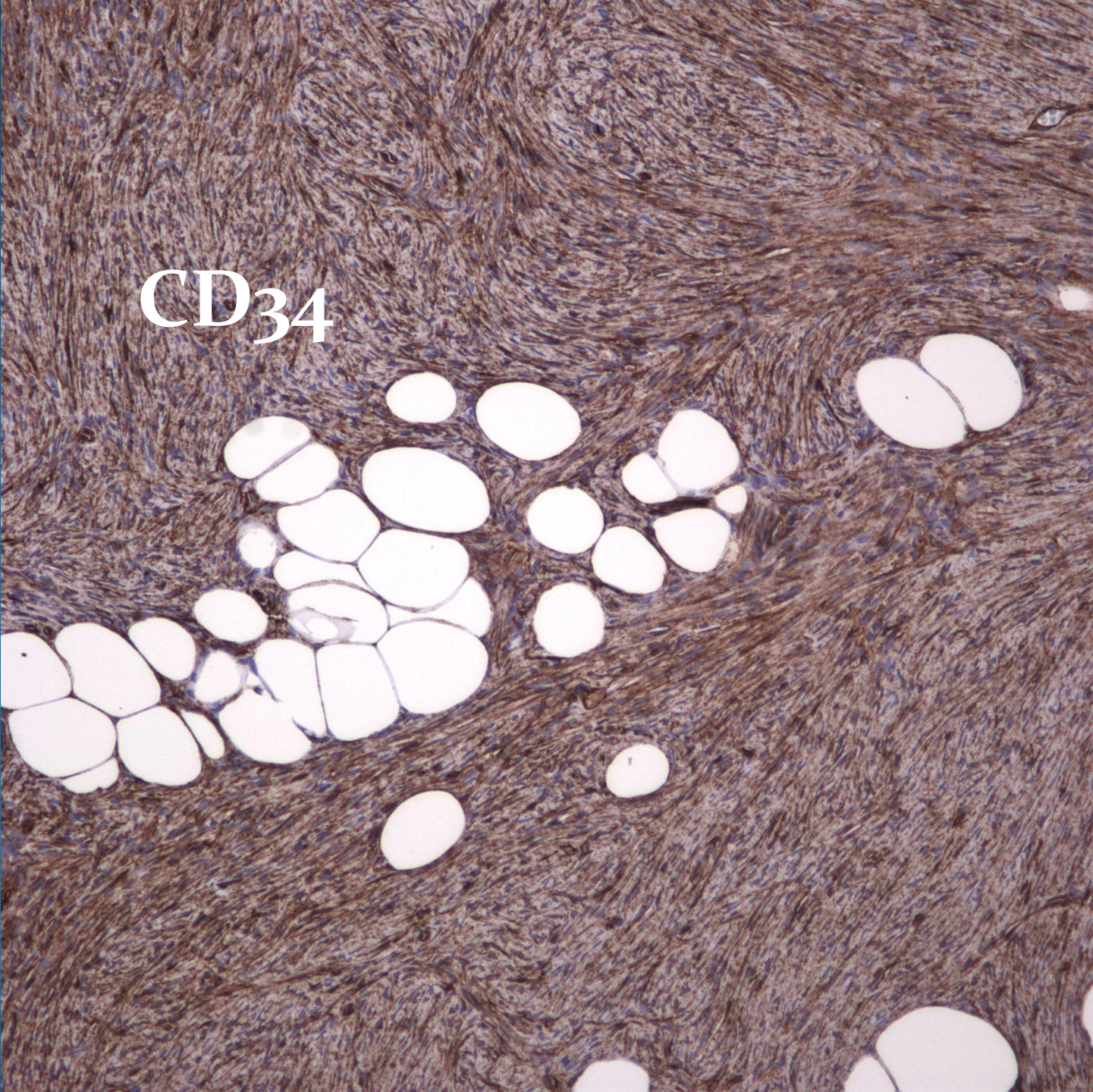
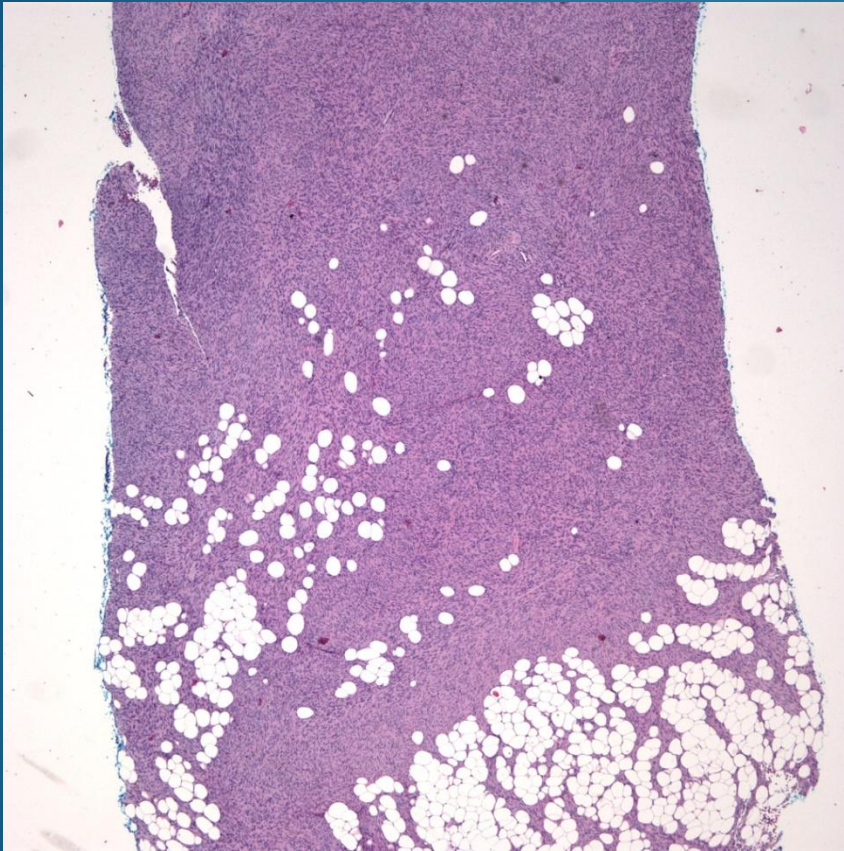


CD34



Dermatofibrosarcoma Protuberans

Pearls



- Spindle cell tumor creating “lace-like” or “sieve-like” appearance with subcutaneous fat
- Cytologically bland with tight storiform
- Beware margins on the tumor
- Beware fibrosarcomatous transformation
- Confirm with IHC-bcl2 and CD34+